

# Coincidental Finding of Sertoli-Leydig Cell Tumor in a Postmenopausal Woman with Mild Hyperandrogenism, Ovarian Teratoma, and Pelvic Organ Prolapse: A Case Report

**Hermína Silonga-Arce, MD\* and Minnou O. Tapia, MD, FPOGS, FPSMFM, FPSUOG**

Department of Obstetrics and Gynecology, San Juan de Dios Hospital

A Sertoli-Leydig cell tumor (SLCT) is an extremely rare type of sex cord stromal tumor of the ovary, which mainly secretes testosterone, thus manifestations of hyperandrogenism commonly appear. This paper shall discuss a case of a postmenopausal woman who presented with pelvic organ prolapse, large left ovarian cyst and mild signs of hyperandrogenism. She underwent total abdominal hysterectomy with bilateral salpingo-oophorectomy, which on microscopic examination of the specimens, revealed a Mature cystic teratoma on the left ovary and an incidental finding of a well-differentiated SLCT, on the grossly normal-looking ovary. This histopathologic diagnosis of SLCT explained the patient's hyperandrogenic characteristics. Authors likewise discussed the proper management of SLCT, including immunostaining and need for adjuvant chemotherapy.

**Key words:** Sertoli Leydig cell tumor, mature cystic teratoma, hyperandrogenism

## Introduction

Sertoli-Leydig cell tumor (SLCT), is a rare sex cord-stromal neoplasm that makes up less than 0.5% of all primary ovarian neoplasms.<sup>1</sup> The majority of cases are found among women in second and third decades of life. Androgenic activity is found in about 50% of cases, which would then typically manifest as amenorrhea, hirsutism, acne, deepening of the voice, decreased breast size, and clitoromegaly. In some patients, no hormonal changes may manifest, but the tumor typically presents as a large ovarian mass causing abdominal pain and increased abdominal circumference on physical examination.<sup>1</sup> Approximately 80% of cases are stage Ia when they are diagnosed, and the tumor is typically unilateral. The overall prognosis for SLCT is good, however it generally depends on the grade and stage of the tumor.

This paper shall discuss a case of a postmenopausal woman who presented with pelvic organ prolapse, large left ovarian cyst and mild signs of hyperandrogenism. Eventually this patient was diagnosed postoperatively with SLCT due to incidental findings on histopathologic examination of the grossly normal-looking ovary. This paper shall discuss appropriate SLCT management strategies and, in particular, indications for conservative surgery and adjuvant chemotherapy.

## The Case

A 52-year-old G4P2 (2022), menopause for 4 years, consulted in a private gynecologist's clinic due to an introital mass. Five years prior to consult, she noticed a 2 cm mass at the introitus accompanied by occasional hypogastric discomfort. She did not experience fever, bowel or urinary complaints, nor vaginal bleeding or discharge. One year prior to consult, patient noted an increase in the size of the introital mass, this time measuring approximately 5cm. This mass progressively increased in size, until

\*For correspondence: h\_silonga@yahoo.com

it reached a length of about 8 cm, 4 months prior to consult. This time, patient reported concomitant flank pain and dysuria. She consulted a doctor, and was prescribed with Cefuroxime 500 mg twice daily for 7 days, which afforded temporary relief. Two weeks prior to consult, upon lifting a very heavy object, she noticed that the introital mass suddenly prolapsed, reaching a maximum length of about 10 cm, again accompanied by dysuria and flank pain. This prompted her to consult a gynecologist.

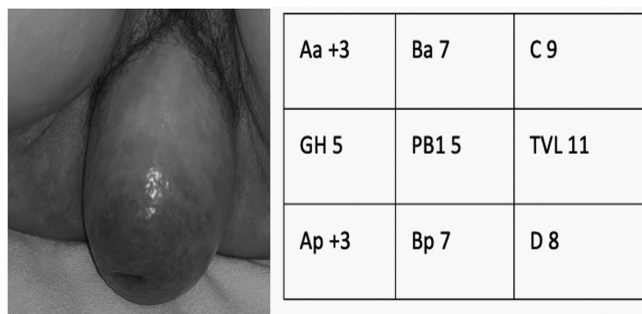
Patient is a known hypertensive, maintained on Losartan. She is a G4P2 (2022), with her 2 term pregnancies delivered vaginally with no complications. She is a non-smoker, non-alcoholic beverage drinker and denied illicit drug use. She has unremarkable gynecologic history.

At the clinic, patient was conscious, coherent, and not in respiratory distress. She had stable vital signs, with BMI of 30.83 kg/m<sup>2</sup> (Obese II). Her skin was generally warm, moist and with good turgor. There were some coarse facial hairs noted on the upper lip, arms and thighs (mFG 7) and several

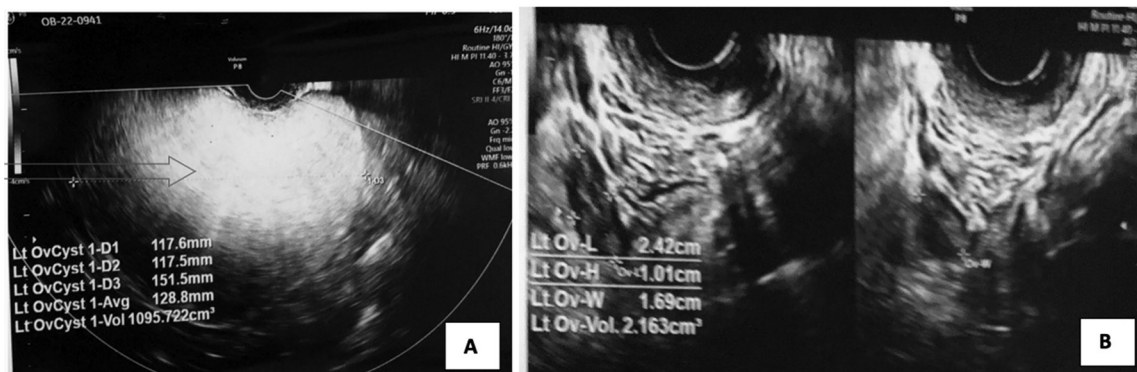
comedonal acne on her face. She had anicteric sclerae and pink palpebral conjunctivae. Examinations of the lungs, heart and breasts were all normal. Abdomen was soft, flabby and nontender. There was a 10cm x 8cm, smooth, movable, nontender mass palpated at the hypogastric area. On perineal and internal examination, the clitoris was normal in size, the anterior and posterior vaginal walls were noted to be lax, and there was a smooth, pinkish mass protruding out of the vagina, with its leading edge (cervix, 2cm x 2cm) prolapsing 9cm beyond the hymen. (Figure 1). The uterus was not enlarged. There was a 10cm x 8cm doughy, movable, nontender mass palpated at the left adnexa, extending to the midline. On rectovaginal examination, patient had a tight anal sphincter, with no intraluminal mass palpated. Bilateral parametria were free and pliable, and there was no uterosacral ligament thickening and nodularity noted.

Transvaginal ultrasound revealed a normal sized uterus with thin endometrium, atrophic right ovary, and left solid ovarian mass that measured 11.76cm x 15cm x 12.88cm, most likely fibroma (Figure 2). Initial diagnoses were the following: G4P2 (2022), Pelvic organ prolapse stage 4, Ovarian new growth, left, probably fibroma; Menopause x 4years, Hypertension Stage II controlled, Obese II. She was scheduled for total abdominal hysterectomy with bilateral salpingoophorectomy.

Intraoperatively, there was no ascites noted. The uterus serosa was not enlarged, with pink, smooth, serosal surface measuring 6cm x 5cm x 2cm. The cervix was smooth measuring 2.5cm x 3cm x 2cm. The right and left fallopian tubes were grossly normal measuring 11cm x 5cm x 0.5cm. The right ovary



**Figure 1.** Prolapsed introital mass, with its leading edge (cervix, 2cm x 2cm) prolapsing 9cm beyond the hymen (POP-Q Stage IV).



**Figure 2.** Transvaginal ultrasound showing a left solid ovarian mass that measured 11.76cm x 15cm x 12.88cm, most likely fibroma (A). The right ovary was atrophic (B).


looked atrophic, measuring 2.5cm x 1.5cm x 1cm (Figure 3), and the left ovary was converted to a smooth unilocular thin walled cystic mass measuring 19cm x 10cm x 5cm containing sebum with tufts of hair (Figure 4).

Microscopically, the left ovary had a well-defined wall lined by stratified squamous epithelium, mature skin appendages (hair follicles and sebaceous glands), and a lumen filled with keratin and hair shafts (Figure 5). The right ovary had an alveolar pattern, open and closed tubules, cellular lobules, and cords made of cells with a black stain. The cells featured 0–1 nucleoli, a round–oval nucleus, and a minimal–moderate quantity of cytoplasm. Leydig cells were observed as heterogeneous nests and clusters within the tumor. Leydig cells were

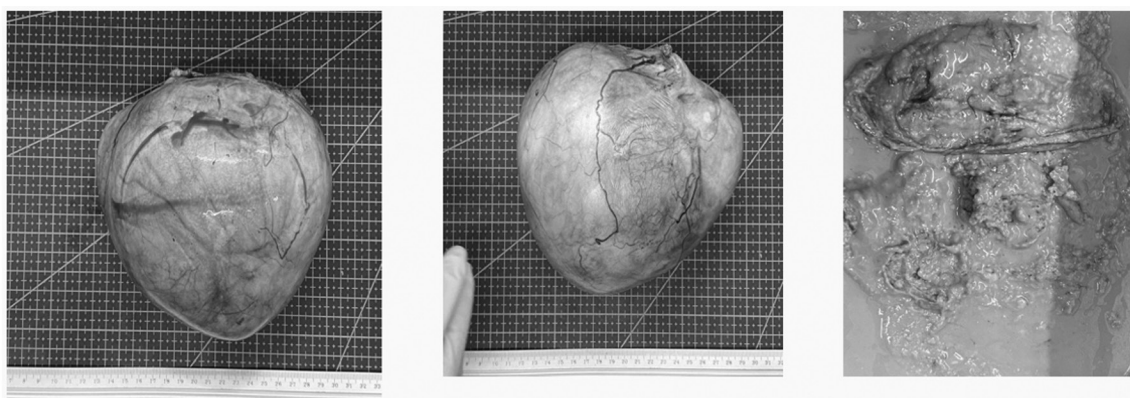
discovered in areas of delicate fibrous stroma (Figure 6). Final histopathologic diagnoses are the following:

Mature Cystic Teratoma, Left Ovary (15cm)  
Well-Differentiated Sertoli-Leydig Cell Tumor (0.3 cm), right ovary; Tumor Confined to the ovary  
Chronic cervicitis with nabothian cysts and squamous metaplasia  
Basal Endometrium  
Unremarkable myometrium and fallopian tubes

Her postoperative course was uneventful and was discharged on the third post-operative day. The stage of the patient was estimated at stage IA, though complete surgical staging was not

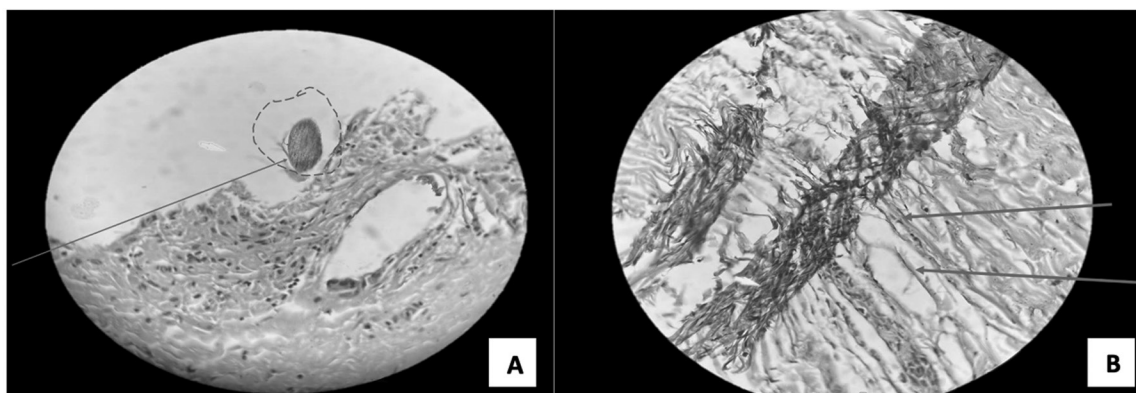


**Figure 3.** Intraoperative findings: the uterus was not enlarged, with pink, smooth serosal surface measuring 6cm x 5cm x 2cm. The cervix was smooth measuring 2.5cm x 3cm x 2cm. The right and left fallopian tubes were grossly normal measuring 11cm x 5cm x 0.5cm. The right ovary was atrophic, measuring 2.5cm x 1.5cm x 1cm, and the left ovary was converted to a smooth unilocular thin walled cystic mass measuring 19cm x 10cm x 5cm.

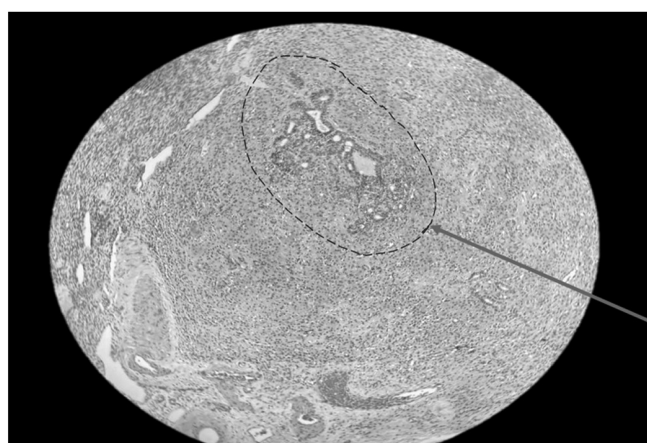


**Figure 4.** The left ovary was converted to a smooth unilocular thin walled cystic mass measuring 19cm x 10cm x 5cm containing mostly sebum with tufts of hair.





**Figure 5.** Microscopic images (LPO) showing hair follicle (A) and fatty and fibrous tissues of mesodermal origin (B).



**Figure 6.** Microscopic image (LPO) of the right ovary showing an alveolar pattern, open and closed tubules, cellular lobules, and cords made of cells with a black stain. Leydig cells (encircled) were observed as heterogeneous nests and clusters within the tumor. Leydig cells were discovered in areas of delicate fibrous stroma.

performed. Stage I SLCTs have a good prognosis. This patient, unfortunately, was lost to follow-up, despite repeated attempts to contact her. Thus, no further endocrinologic laboratory work-ups nor immunostaining were done.

## Discussion

### A. Sertoli-Leydig Cell Tumors

Hyperandrogenism caused by ovarian tumors accounts for approximately 1% of all cases of hyperandrogenism. These are usually caused by ovarian sex cord stromal tumors, which are quite rare, accounting for only 5%–8% of all ovarian neoplasms.<sup>2,3</sup> A Sertoli-Leydig cell tumor (SLCT)

is an extremely rare type of sex cord stromal tumor of the ovary, which mainly secrete testosterone, thus manifestations of virilization may appear.

The Sertoli and Leydig cells are normally located in the male reproductive glands (testes). The Sertoli cells contribute to the process of spermatogenesis, while the Leydig cells release male sex hormones.<sup>5</sup> When these cancerous cells are found in a woman's ovaries, they release the male sex hormones and thus patients present with amenorrhea, hirsutism, acne, deepening of the voice, decreased breast size, and clitoromegaly. In some patients, no hormonal changes may manifest, but the tumor typically presents as a large ovarian mass causing abdominal pain and increased abdominal circumference on physical examination. Our index case presented with mild hirsutism and facial acne as the only hyperandrogenic signs, with a normal-looking affected ovary. The diagnosis of SLCT was only a coincidental finding on histopathological examination of a seemingly normal ovary. A similar case was reported by Tsuzuki, et al (2017)<sup>4</sup>, where they described a 66 year old woman who presented with irregular postmenopausal bleeding and endometrial hyperplasia, but with grossly normal-looking bilateral ovaries, on exploration. It was only during histopathologic examination when they discovered SLCT on the left ovary.

Sertoli-Leydig cell tumors can be solid, cystic, or mixture of both. Imaging studies such as ultrasound, CT, and MRI are useful for diagnosis. Color Doppler is used to characterize SLCTs because these tumors tend to be well vascularized. However, about 20% of the SLCTs cannot be visualized on imaging studies, because of their small or microscopic size.<sup>4</sup> For our

index case, only a 0.3 cm area at the right ovary showed these cancerous Sertoli-Leydig cell tumor cells, thus was not established preoperatively.

SLCTs are histologically classified into well-differentiated, moderately differentiated, poorly differentiated, with a retiform pattern, with heterologous elements (mucoprotein, focal carcinoid elements, cartilage, etc), and mixed. Well-differentiated tumors are mostly benign, and tumors other than well differentiated type, or tumors with retiform or heterologous elements pattern can behave in a malignant manner.<sup>4,6</sup> Our index case had a well-differentiated SLCT, stage 1A, which confers a good prognosis overall.

Ideally, immunostaining would be most ideal to confirm a diagnosis of SLCT. Vimentin, keratin,  $\alpha$  inhibin, and calretinin are the most useful immunohistochemical markers of sex cord stromal tumors, which could help differentiate SLCTs from other malignancies.<sup>4,7</sup> From a genetic point of view, SLCTs are associated with a somatic mutation in the DICER-1 gene. This mutation is found in approximately 60% of cases.<sup>8</sup>

Surgery is the gold standard treatment for SLCTs. Total hysterectomy with bilateral salpingo-oophorectomy with adjuvant chemotherapy is recommended for stage 1C and more advanced stages. However, conservative surgery (unilateral salpingo-oophorectomy) could be performed for young patients, with early stage cancer (Stage 1A), who desire fertility preservation.<sup>4,9</sup> Adjuvant chemotherapy should be proposed for stage 1A when poor prognostic factors are present (poor differentiation, retiform pattern, or heterologous elements).

## **B. Mature Cystic Teratoma and Pelvic Organ Prolapse**

The index case underwent total abdominal hysterectomy with bilateral salpingo-oophorectomy, not because of an SLCT, but a preoperative diagnosis of a large ovarian cyst and pelvic organ prolapse. She exhibited mild hyperandrogenic characteristics (mild hirsutism, mFG 7, and acne) which was largely overlooked by the attending physician, and considered generally non-contributory to the case at hand. It was fortunate that patient experienced apparent indications for immediate surgery, which

led to the definitive removal of the unexpected cancerous cells.

Mature cystic teratoma is the most frequent germ cell tumor and accounts for more than 95% of all ovarian teratomas. These tumors are mostly benign. It is composed of tissues that recapitulate the ectoderm, endoderm and mesoderm. In most cases, this tumor contains non-secreting tissues, however very rarely, some mature cystic teratoma can produce testosterone leading to isolated virilization.<sup>10,11</sup> Teratomas can present as a solid or cystic mass and usually have a characteristic ultrasound appearance (stipplings, areas of fat and calcification), which allows for an accurate sonographic diagnosis most of the time.<sup>10</sup> Our patient, however, was preoperatively diagnosed with ovarian fibroma due to sonographic findings indicative of a “solid tumor”.

In postmenopausal patients such as in our index case, oophorectomy is the preferred surgical treatment, while in young women in whom fertility is an issue, a conservative surgery in the form of oophorocystectomy is preferred.

Pelvic organ prolapse (POP) is the descent of one or more of the anterior vaginal wall, posterior vaginal wall, uterus (cervix) or the apex of the vagina (vaginal vault or cuff scar after hysterectomy) from their normal anatomical position into the vaginal canal. The occurrence of POP is quite common, with up to 40-60% of all parous women estimated to be affected during their lifetime.<sup>12,13</sup> Our index patient suffered from Stage IV POP, with her cervix prolapsing 9cm beyond the hymenal ring. Normally, a vaginal hysterectomy with anterior and posterior repair would be the preferred surgical method for Stage IV POP. However, in this case, the presence of the large ovarian cyst precluded the vaginal route, and thus an abdominal hysterectomy was performed.

## **Conclusion**

Sertoli-Leydig cell tumors (SLCTs) are very rare malignant tumors that can cause hyperandrogenism. A diagnosis of SCLT is usually established by clinical presentation of virilization or defeminization plus findings of an ovarian mass on imaging studies. However, in 20% of cases, SCLTs are not clinically apparent, and are diagnosed only as an incidental finding upon histopathologic examination. Surgery is the gold standard treatment for SLCTs, but

conservative surgery could be performed for young patients, with early stage cancer who desire fertility preservation.

## References

1. Gouy S, Arfi A, Maulard A, Pautier P, Bentivegna E, Leary A, Chargari C, Genestie C, Morice P. Results from a monocentric long-term analysis of 23 patients with ovarian Sertoli-Leydig cell tumors. *Oncologist* 2019 May; 24(5):702-9.
2. Sebastien G, Alexandra A, Amandine M, Patricia P, Enrica B. Results from a monocentric long-term analysis of 23 patients with ovarian Sertoli-Leydig cell tumors. *Oncol* 2018; 23: 1–8.
3. Chen D, Zhang J, Shi W, Wang XH, Zhang SW. Postmenopausal mild hirsutism and hyperandrogenemia due to ovarian Sertoli-Leydig cell tumor: A case report. *Heliyon* 2020 Apr; 6(4): e03746.
4. Tsuzuki Y, Kikuchi I, Nojima M, Yoshida K, Hashizume A, Tomita S. A Case Report: Ovarian Sertoli-Leydig cell tumor with hyperestrogenism and endometrial hyperplasia in a postmenopausal woman. *Jpn Clin Med* 2017; 8: 1179066017695239.
5. MedlinePlus-National Library of Medicine. Sertoli-Leydig cell tumor. Available at <https://medlineplus.gov/ency/article/001172.htm>. Accessed on June 20, 2024.
6. Cabrera-Cantú F, Urrutia-Orsorio M, Valdez-Arellano F, Rivadeneyra-Espinoza L, Papaqui A, Soto-Vega E. Sertoli-Leydig cell tumor in a 12-year-old girl: a review article and case report. *Arch Gynecol Obstet* 2014; 290: 791–6.
7. Zhao C, Vinh TN, McManus K, Dabbs D, Barner R, Vang R. Identification of the most sensitive and robust immunohistochemical markers in different categories of ovarian sex cord-stromal tumors. *Am J Surg Pathol* 2009; 33: 354–66.
8. Goulvent T, Ray-Coquard I, Borel S, et al. DICER1 and FOXL2 mutations in ovarian sex cord-stromal tumours: A GINECO Group study. *Histopathology* 2016;68:279–85.
9. Gui T, Cao D, Shen K, et al. A clinicopathological analysis of 40 cases of ovarian Sertoli-Leydig cell tumors. *Gynecol Oncol* 2012; 127: 384–9.
10. Shanbhogue AKP, Shanbhogue DKP, Prasad SR. Clinical syndromes associated with ovarian neoplasms: a comprehensive review. *Radiographics* 2010; 30: 903–19. 10.1148/rg.304095745
11. Palha A, Cortez L, Tavares AP, Agapito A. Leydig cell tumour and mature ovarian teratoma: rare androgen-secreting ovarian tumours in postmenopausal women. *BMJ Case Rep* 2016; 2016: bcr2016215985.
12. Gray TG, Giarenis I. Surgical Management of pelvic organ prolapse. *Obstet Gynaecol Reprod Med* Sept 2021; 31(9):245-52.
13. Ko KJ, Lee KS. Current surgical management of pelvic organ prolapse: strategies for the improvement of surgical outcomes. *Investig Clin Urol* 2019 Nov; 60(6):413-24.